



Abstract

Dental implant failure, is defined as a failure of osseo-integration between the bone tissue and dental implant or the formation of fibrotic tissue between dental implant and bone tissue.

INTRODUCTION

Osseous implant, is a surgical component that interfaces with the bone of jaw or skull to induce or increase support of dental prosthesis like bridges, dentures, facial prosthesis crowns and to act as an orthodontic anchor called (Mini Implant) to accelerate the treatment. On the other hand, the Dental Implant failure, is defined as a failure of osseointegration between the bone tissue and dental implant or the formation of fibrotic tissue between dental implant and bone tissue. There are many factors related to this failure, like systemic and environment factors, Local and surgical factors, prosthetic failure, esthetic failure. Other types dental implant failure include:

- 1-Pre-operative dental implant failure
- 2-Intra-operative dental implant failure ,
- 3-Post-operative dental implant failure •

Objectives

The aim of this research to promote patient's oral hygiene with proper surgical and mechanical technique and to use Bio-active implant to prevent of dental implant failure

METHODS & MATERIAL

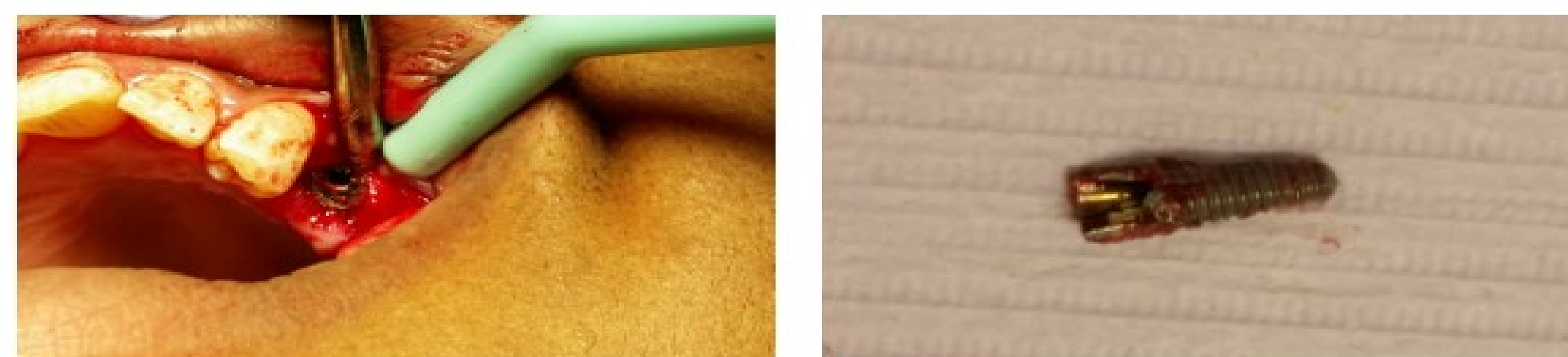
This study included patients receiving Nobel Bio-care implants during 2014-2016. ALL the them had signed their informed consent to the implant treatment. All the patients underwent a primary evaluation, include radiographic examination, review of past medical and dental history and oral hygiene practice. Diagnostic evaluation was done using cone beam computed tomography (OPG, Diagnostic Casts).The prosthodontic treatment was included by using the diagnostic casts which were fabricate and mounted on semi adjustable articulators with face bow transfer to determine the jaw relationships, vertical, and horizontal distance. The functional and esthetic preparation were evaluated before the surgical procedures using fabricate for the surgical guide implant placement in relation to planned prosthesis. Prophylaxis antibiotic (Amoxicillin 500 mg) as well as chlorhexidine mouth rinse was subscribed to the patients.

Immediate placing dental implant with low torqueing will increase the fail

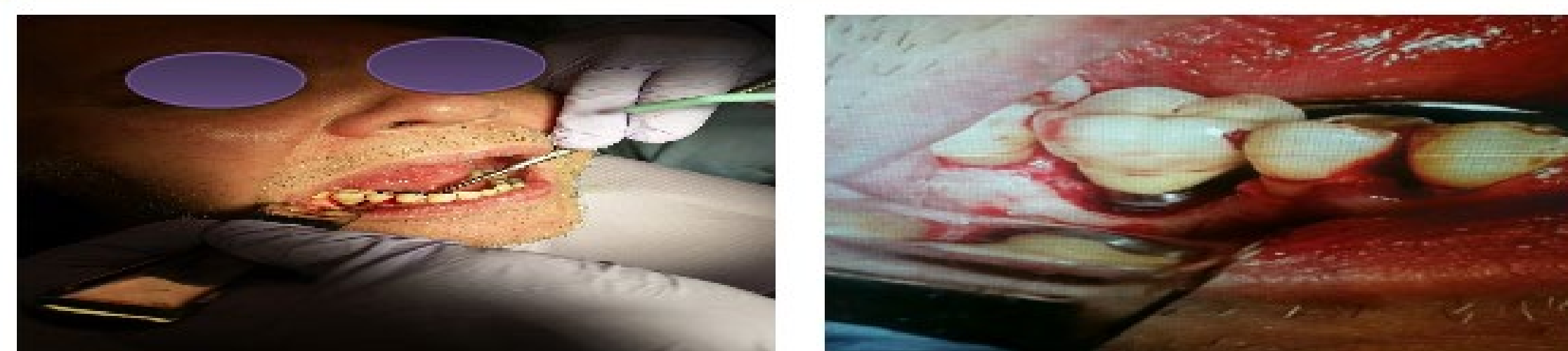
The over torqueing is a critical factor when placing immediate single implant body in a patient mouth and the torques ranging from 25 to 35 Ncm with immediate loading (A single implant inserted flapless with medium or high insertion torque: a 6-month follow-up of a split-mouth randomized controlled trial. Gioacchino Cannizzaro, et al. 2012).

Patient #	Implant position	Post-extractive	Bone quality	Insertion torque	Implant length	Pain at 1 week	Pain at 6 weeks
5	13	No	Hard	30 Ncm	13 mm	None	Severe
9	45	No	Medium	25 Ncm	10 mm	None	Moderate
11*	15	Yes	Medium	30 Ncm	10 mm	Severe	Already removed
15	45	No	Hard	25 Ncm	10 mm	None	Already removed
20	14	No	Medium	25 Ncm	10 mm	None	Severe
23	36	No	Hard	25 Ncm	10 mm	Severe	Already removed
40	36	No	Medium	25 Ncm	11.5 mm	Severe	Already removed

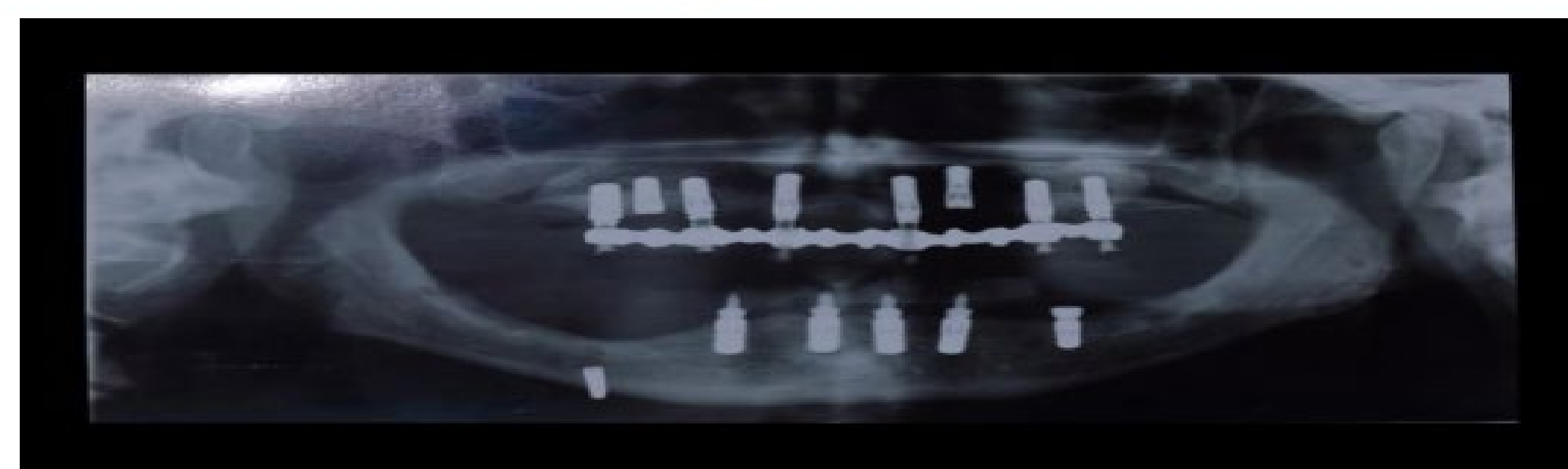
Two dental implants fractured due to over torqueing



Marginal bone loss due to occlusal overload



Panoramic X-ray shows dental implant migration



Significance

The bio -active type include:

Laser -Lok type.

Strauman SLA active type.

Dual acid etch, Zimmer dental type.

The laser-lok type has nano-structure surface that enhance the osseointegration and prevent or control the fibrous capsule formation, also increase the bone cell differentiation.

It can control and organize microstructure that work on cellular level and produce supra crestal soft tissue attachment.

Bio-active type can control of plaque formation, better transfer stress and distribution to alveolar bone crest.

All bio-type implants have hydrophilic surfaces that allow to bind protein to surface attachment.

Calcium phosphate surface has directly attachment of bone and will increase the osseointegration and proliferation of cells.

The medium torqueing (25 to 35Ncm) is risk factor when placing immediate single implant body in patient mouth. When placing the implant with a proper healing time (6 months for maxilla and 4 months for mandible) with torques between 30Ncm -35Ncm will increase the success rate.

(Gioacchino Cannizzaro, et al. 2012

CONCLUSION

Dental implant failure is still challenge to the surgeon. Good diagnosis and selection the patients are the key point for success treatment. Full mouth x-ray for patient and if the patient has any systemic diseases or periodontitis, these considerations must be taken carefully. Smoker patient or patient had chemotherapy or patient with bad habits like alcohol consumption. Control of possible risk factors and skillful decontamination of implant surfaces influence the overall outcome of the treatment. In general poorly controlled diseases, including uncontrolled periodontitis leading to peri-mucositis and per-implantitis and in the final stage implant failure. It is recommended to insert single implants with high insertion torques (>35 Ncm), to reduce or to minimize early implant failures, when loading them immediately.

References

- 1-Gioacchino Cannizzaro, Michele Leone, Vittorio Ferri, Paolo Viola, Gelpi Federico, Marco Esposito Immediate loading of single implants inserted flapless with medium or high insertion torque: a 6-month follow-up of a split-mouth randomised controlled trial.
- 2- Dynamic fatigue performance of implantabutment assemblies with different tightening torque values by Dandan Xia a,b, Hong Lin a,b, Shenpo Yuan a,b, Wei Bai a,b and Gang Zheng a,b, a Department of dental materials, School and Hospital of Stomatology, Peking University, Beijing, China b National engineering laboratory for Digital and Material Technology of Stomatology, Peking University, Beijing, China
- 3-Peri-implant Diseases A Review of Treatment Interventions Georgios E. Romanos, DDS, PhD, Prof. Dr. med. dentia, Fawad Javed, BDS, PhD, Rafael Arcosio Delgado-Ruiz, DDS, MSc, PhDc, José Luis Calvo-Guirado, DDS, MS, PhD.
- 4- Persistent Pain and Neurosensory Disturbance After Dental Implant Surgery Pathophysiology, Etiology, and Diagnosis by Mohamad Al-Sabbagh, DDS, MSA, Jeffrey P. Okeson, DMD, Mohd W. Khalaf, DDS, Ishta Bhavsar, BDS.
- 5-Esthetic failure in implant Dentistry by Rodrigo Fuentealba, DDS, Jorge Jofre, DDS, PhD.
- 6-Persistent Pain and Neurosensory Disturbance After Dental Implant Surgery prevention and treatment, by Mohamad Al-Sabbagh, DDS, MS, Jeffrey P. Okeson, DMD, Elizangela Bertoli, DDS, Denielle C. Medynski, DMD
- 7-Mohd W. Khalaf, Moy PK, Medina D, Shetty V, et al. Dental implant failure rates and associated risk factors. Int J Oral Maxillofac Implants 2005;20(4):569-77.
- 8-Chen H, Liu N, Xu X, et al. Smoking, radiotherapy, diabetes and osteoporosis as risk factors for dental implant failure: a meta-analysis. PLoS One 2013;8(8):e71955.
- 9-Complications associated with implant-retained removable prosthodontics, by Farhad Vahidi, DMD, MSD, Gitanjali Pinto-Simai, DDS.
- 10-Granzstrom G. Osseointegration in irradiated cancer patients: an analysis with respect to implant failures. J Oral Maxillofac Surg 2005;63(5):579-85.
- 11-Gu L, Yu YC. Clinical outcome of dental implants placed in liver transplant recipients after 3 years: a case series. Transplant Proc 2011;43(7):2678-82.
- 12-Nibali L, Tatarakis N, Needleman I, et al. Clinical review: association between metabolic syndrome and periodontitis: a systematic review and meta-analysis. J Clin Endocrinol Metab 2013;98(3):913-20.
- 13-Kumar PS, Mason MR, Brooker MR, et al. Pyrosequencing reveals unique microbial signatures associated with healthy and failing dental implants. J Clin Periodontol 2012;39(5):425-33.
- 14-Katz J, Seltzer Z. Transition from acute to chronic postsurgical pain: risk factors and protective factors. Expert Rev Neurother 2009;9(5):723-44. 37. Kehlet H, Jensen TS, Woolf CJ. Persistent postsurgical pain: risk:

- Acknowledgments

- 1-Christine Rush low, PhD., Professor
- 2-Mazen Nat our, DmD
- 3-Kenneth E . Fleischer, DDS.
- 4- Carolyn Swain DDS.